

# Treatment of Medial Collateral Ligament Injuries

Ryan G. Miyamoto, MD  
Joseph A. Bosco, MD  
Orrin H. Sherman, MD

Dr. Miyamoto is Sports Medicine Fellow, Steadman-Hawkins Clinic, Vail, CO. Dr. Bosco is Assistant Professor, Department of Orthopaedic Surgery, and Vice Chairman for Clinical Affairs, NYU-Hospital for Joint Diseases, New York, NY. Dr. Sherman is Associate Professor and Chief of Sports Medicine, Department of Orthopaedic Surgery, NYU-Hospital for Joint Diseases.

Dr. Bosco or a member of his immediate family serves as a board member, owner, officer, or committee member of the American Orthopaedic Society for Sports Medicine; is affiliated with the bulletin of the Hospital for Joint Diseases; and has received research or institutional support from Johnson & Johnson. Dr. Sherman or a member of his immediate family has received research or institutional support from Arthrex, Mitek, and Smith & Nephew. Neither Dr. Miyamoto nor a member of his immediate family has received anything of value from or owns stock in a commercial company or institution related directly or indirectly to the subject of this article.

Reprint requests: Dr. Miyamoto, Steadman-Hawkins Clinic, 181 West Meadow Drive, Vail, CO 81675.

*J Am Acad Orthop Surg* 2009;17:152-161

Copyright 2009 by the American Academy of Orthopaedic Surgeons.

## Abstract

The medial collateral ligament is the most frequently injured ligament of the knee. The anatomy and biomechanical role of this ligament and the associated posteromedial structures of the knee continue to be explored. Prophylactic knee bracing has shown promise in preventing injury to the medial collateral ligament, although perhaps at the cost of functional performance. Most isolated injuries are treated nonsurgically. Recent studies have investigated ligament-healing variables, including modalities such as ultrasound and nonsteroidal anti-inflammatory drugs. Concomitant damage to the anterior or posterior cruciate ligaments is a common indication to surgically address the high-grade medial collateral ligament injury. The optimal treatment of multiligamentous knee injuries continues to evolve, and controversy exists surrounding the role of medial collateral ligament repair/reconstruction, with data supporting both conservative and surgical management.

The treatment of medial collateral ligament (MCL) injuries in the knee continues to evolve as more is discovered about MCL anatomy and biomechanics, as well as about the factors that affect its healing. Because the MCL is the most commonly injured ligament in the knee, the treatment principles of MCL tears are important to primary care doctors and orthopaedic surgeons alike.<sup>1</sup> Prophylactic knee bracing has become an increasingly popular modality for preventing knee injuries in both amateur and professional athletes. Although nonsurgical management of isolated MCL injuries remains the preferred treatment in most cases, controversy exists regarding the ideal treatment when there is concomitant damage to the anterior cruciate ligament (ACL) or posterior cruciate ligament (PCL).

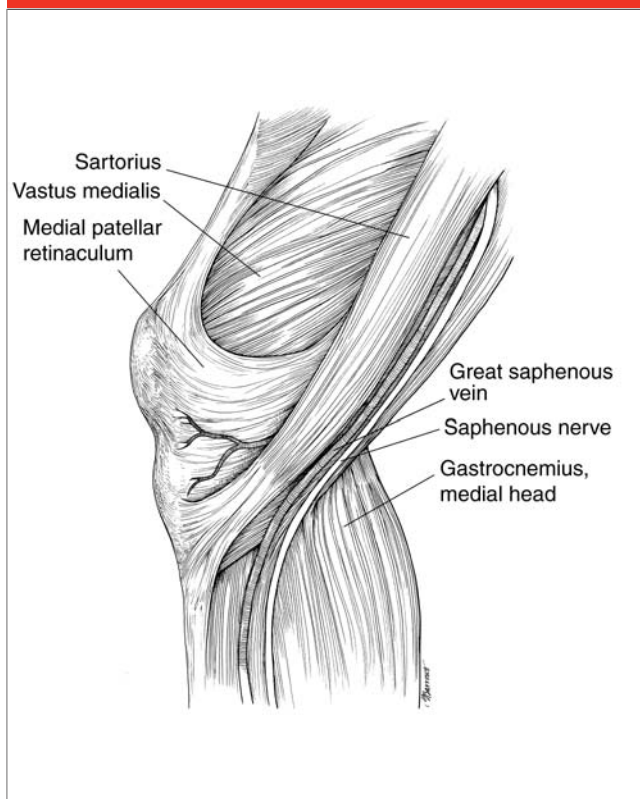
## Anatomy and Biomechanics

It is crucial to understand the complex structure and function of the medial knee and the MCL before developing a treatment regimen for injuries to this structure and for associated knee injuries. Sims and Jacobson<sup>2</sup> retrospectively reviewed the charts of 93 patients who were treated surgically for medial-side injuries and noted that 88% had injury to more than one medial or posteromedial structure, most commonly the posterior oblique ligament (POL).

## Anatomy of the Medial Knee

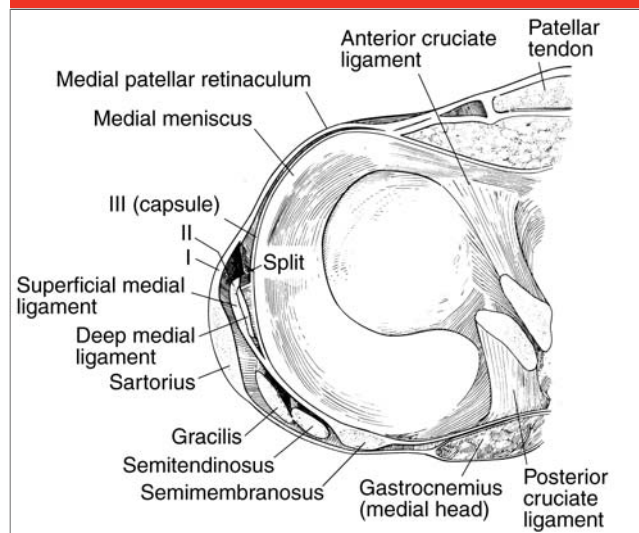
The descriptions of and terminology regarding the structures of the medial knee have been revisited many times, but the article most frequently cited is

Figure 1



Layer I of the medial aspect of the knee.

Figure 2



Cross-section illustrating the layers of the medial knee. Layer I consists of the fascial layer investing the sartorius muscle. Layer II consists of the superficial medial collateral ligament, the ligaments of the posteromedial corner of the knee, and the medial patellofemoral ligament. Layer III consists of the true capsule of the knee joint and the deep medial collateral ligament. (Reproduced with permission from Warren LF, Marshall JL: The supporting structures and layers on the medial side of the knee: An anatomical analysis. *J Bone Joint Surg Am* 1979;61:56-62.)

the anatomic study performed by Warren and Marshall,<sup>3</sup> who described a three-layer concept of the anatomy. Layer I, the most superficial, consists of the fascial layer investing the sartorius muscle (Figures 1 and 2). This layer extends posteriorly to overlie both heads of the gastrocnemius muscle and the neurovascular structures of the popliteal fossa. Anteriorly, layer I blends with layer II approximately 2 cm anterior to the superficial MCL. Distally, layer I joins the periosteum of the tibia near the insertion site of the sartorius.

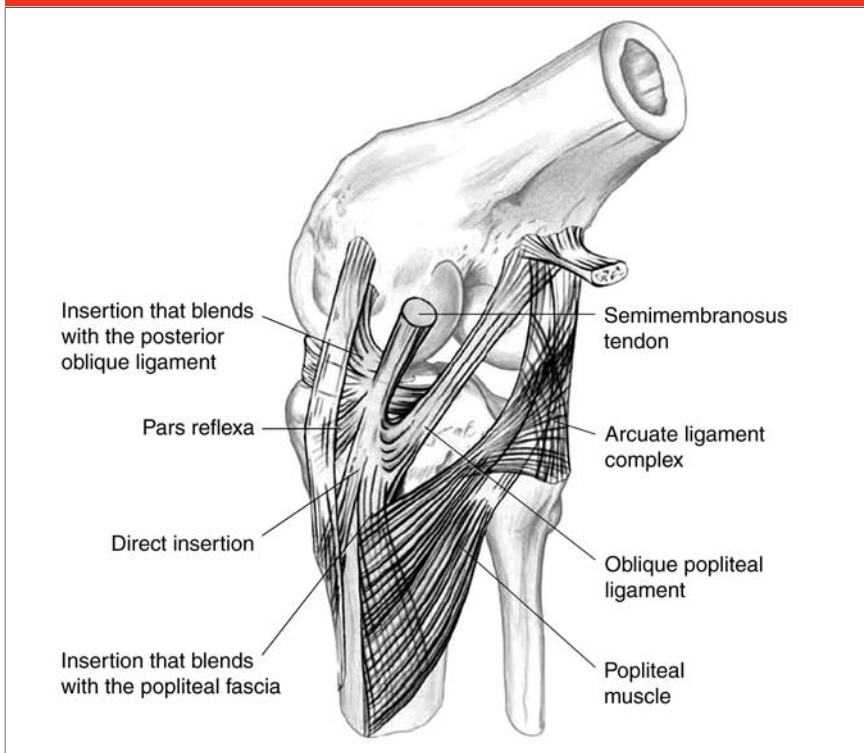
Layer II consists of the superficial MCL and the ligaments of the posteromedial corner of the knee as well as the medial patellofemoral ligament (Figure 2). At the posteromedial corner of the knee, layer II blends with layer III to form a pouch

known as the posteromedial capsule. This pouch envelops the medial condyle of the femur. The fibers of the posteromedial capsule are joined by the tendon and sheath of the semimembranosus. The semimembranosus has several insertion sites, providing further support for this area of the knee (Figure 3). A portion of the semimembranosus tendon inserts directly into the posteromedial corner of the tibia just distal to the joint line. Several of the anterior fibers of the tendon proceed around the medial tibia distal to the joint line and insert deep to the superficial medial ligament. The tendon sheath of the semimembranosus muscle also makes structural contributions to the medial knee by sending out various fiber tracts. One extension, the oblique popliteal ligament, is sent up-

ward over the medial femoral condyle and crosses the back of the knee to the lateral femoral condyle.

Layer III consists of the true capsule of the knee joint and the deep MCL. Except at its patellar margin, the capsule is a discrete structure. Anteriorly, the capsule provides no stabilizing effects and serves only to envelop the fat pad. Beneath the superficial MCL, the capsule thickens and forms a set of short, vertically oriented bands known as the deep MCL (ie, medial capsular ligament). The deep MCL extends from the femur to the periphery of the medial meniscus. The portion of the capsule that joins the meniscus to the tibia is short, providing only a small range of motion (ROM) for the anterior horn. Approximately 2 cm posterior to the superficial MCL, layers II and

**Figure 3**



Semimembranosus insertions in the knee. (Reprinted with permission from Sims WF, Jacobson KE: The posteromedial corner of the knee: Medial-sided injury patterns revisited. *Am J Sports Med* 2004;32:337-345.)

**Table 1**

**Medial Knee by Layer and Aspect**

Layer	Anterior	Middle	Posterior
I	Layer of fascia	Layer of fascia	Layer of fascia
II	No significant ligamentous structure connecting femur to tibia	Superficial medial collateral ligament (longitudinal fibers)	Posteromedial capsule
III	No significant ligamentous structure connecting femur to tibia	Deep medial collateral ligament	Posteromedial capsule

Reprinted with permission from Robinson JR, Sanchez-Ballester J, Bull AM, Thomas Rde W, Amis AA: The posteromedial corner revisited: An anatomical description of the passive restraining structures of the medial aspect of the human knee. *J Bone Joint Surg Br* 2004; 86:674-681.

III blend with the meniscofemoral portion of the deep MCL to envelop the posteromedial corner of the joint.

### Anatomy of the Medial Collateral Ligament

The superficial MCL is composed of parallel and oblique fibers. The ante-

rior parallel fibers of the MCL have a distinct vertical margin, whereas the posterior fibers become more oblique in orientation. The femoral attachment of the MCL is approximately 1 cm anterior and distal to the adductor tubercle; its parallel fibers run distal to the anteromedial

tibial crest approximately 4.5 cm distal to the medial joint line, with fibers blending tangentially with the tibial periosteum, posterior to the pes anserinus.<sup>4,5</sup>

Anteriorly, a bursa lies between the superficial and deep MCL. The deep MCL is made up of the meniscofemoral and the meniscotibial ligaments. Although the layers exist as distinct structures in the middle one third of the medial knee, they blend together posteriorly, along with the tendon sheath of the semimembranosus, to form the posteromedial capsule. This layering concept was confirmed and simplified by Robinson et al,<sup>4</sup> who described the structures according to their layer and position in the coronal plane (Table 1).

### Biomechanics of the Medial Collateral Ligament

Biomechanically, the superficial MCL is the primary restraint to valgus stress in the knee. Wymenga et al<sup>5</sup> have shown that transection of the MCL results in 2° to 5° of laxity or 3 to 5 mm of joint opening when a valgus stress is applied, whereas transection of both the MCL and the posteromedial capsule results in 7° to 10° of laxity, thus illustrating the functional coordination of these two structures. During flexion, the anterior and posterior portions of the MCL are subject to differing degrees of force. The anterior fibers are tensioned as the femoral attachment site is rotated upward during flexion. Conversely, the posterior fibers rotate underneath the anterior fibers during flexion and thus remain relaxed. During extension, the anterior fibers are relaxed and the posterior fibers are tensioned. Most biomechanical studies and computational models have concluded that the level of strain in the MCL varies with location (eg, femoral origin, midsubstance, tibial insertion) and the

amount of flexion being tested.<sup>6</sup> The largest strain on the MCL occurs during valgus loading, with forces concentrated near the femoral insertion site. This finding correlates well with clinical data showing that the femoral insertion site is most commonly damaged in MCL injuries. Additionally, the superficial MCL plays a secondary role in resistance to external rotation and anterior/posterior translation. Meanwhile, the deep MCL acts as a secondary stabilizer against valgus stress.

### Etiology and Mechanism of Injury

The incidence of MCL injury, particularly grade I and II sprains, is likely much higher than is reported. MCL injuries can be seen in both contact and noncontact sports when valgus stress is applied to a flexed knee. Additional mechanisms of injury include an external rotation pivoting injury, a blow to the anterolateral knee, and frank knee dislocation. Concomitant injuries to associated structures about the knee (eg, ligaments, menisci) are frequent and increase in likelihood with increasing severity of the sprain. Fetto and Marshall<sup>7</sup> reported associated injury rates as high as 78% in grade III sprains.

### Prophylactic Knee Bracing

Prophylactic knee bracing has been the topic of much debate over the past 30 years, particularly in regard to its role in collegiate athletics. Although the knee is the most frequently injured body part in collegiate and high school football players, the use of bracing has been contested because of concerns regarding possible compromise in athletic performance.<sup>8</sup> Biomechanical testing of off-the-shelf prophylactic knee braces has proved their func-

tional capacity in protecting the MCL. In their comparison of eight commercial knee braces using a surrogate knee model, Brown et al<sup>9</sup> demonstrated that all braces provided 20% to 30% increased MCL strain relief, knee stiffness, and valgus failure load in a fully extended knee. In their review, Najibi and Albright<sup>10</sup> noted that despite the biomechanical protection afforded by prophylactic knee braces, their use may come at the cost of functional performance, namely, increased muscle relaxation pressures, blood lactate levels, oxygen consumption, and heart rate. Greene et al<sup>11</sup> noted that objective effects on speed and agility varied widely among particular braces, but they also noted that the players' perception of the ability of the brace to protect and/or affect their performance was an important component of brace wear.

To date, only two large epidemiologic studies have been performed regarding brace use. The first was a prospective, randomized study of cadets who played intramural tackle football at the United States Military Academy at West Point.<sup>12</sup> Greater than a twofold incidence of knee injuries was shown in the group not wearing prophylactic knee braces. The effectiveness of prophylactic knee bracing was also evaluated in a study of football players in the Big Ten Conference.<sup>8</sup> Although not statistically significant, the injury rates in practices and in games were lower for players most at risk for MCL injury (ie, linebackers, tight ends) who were wearing braces. Compliance with brace wear was shown to vary widely with position and players' perceptions of the benefits and risks of the devices.

Although there is no consensus on the necessity of brace wear in participants in collegiate football and other contact sports, it appears that prophylactic knee

braces do provide some protection to the MCL. Equally important to more widespread use of prophylactic knee bracing will be studies demonstrating that there is no limitation of function when braces are worn as well as putting an end to players' perceptions that performance is hampered while wearing the braces.

### Diagnosis

Close attention to a patient's history will often lead a clinician to suspect injury to the MCL, particularly when the mechanism includes a valgus blow to the knee. Because of the associated injuries seen with MCL damage, a thorough knee examination is always required. Careful palpation along the course of the ligament is necessary. Tenderness over the adductor tubercle or proximal medial tibia may indicate injury at the origin or insertion sites of the ligament. Additionally, pain over the medial joint line may indicate an associated medial meniscus tear or chondral injury.

The crucial test for MCL injury is gentle valgus stress testing with the knee in 30° of flexion. The injured leg is placed over the side of the examination table to allow relaxation of the thigh musculature. Comparison with the contralateral knee is necessary to compare the amount of joint line opening. Based on the American Medical Association classification, an injury is defined by the amount of joint line opening: grade I, <5 mm of medial joint line opening; grade II, 5 to 10 mm of joint line opening; and grade III, >10 mm of joint line opening.<sup>13</sup>

Experienced examiners may also be able to judge the quality of the end point with valgus stress. This defines the degree of the injury, as opposed to the grade. A patient with a first-degree sprain presents with ten-

derness over the MCL but no instability. With a second-degree sprain, there is increased valgus laxity, but a firm end point still exists. A third-degree sprain has no end point to valgus stress. The terms “grade” and “degree” are often incorrectly used interchangeably in scientific papers on this topic, making it difficult to accurately analyze some studies.

Next, valgus stress testing should be performed with the knee in full extension. This tests the integrity of both the MCL and the POL. Increased joint opening in full extension should alert the physician not only to POL injury but also to possible concomitant cruciate ligament injuries. The presence of an associated hemarthrosis, as opposed to local soft-tissue swelling seen in MCL injuries, should also warn the examiner of possible cruciate ligament injury.

Radiographic evaluation of a knee with a chronic MCL injury may reveal calcification within the substance of the ligament, frequently in the proximal origin of the ligament. This heterotopic bone is known as a Pellegrini-Stieda lesion and can be seen in patients with severe injuries, including subluxation/dislocation. This calcification may be symptomatic, causing debilitating pain. Although local anesthesia can be used for symptomatic treatment of these chronic lesions, promising results have been seen with open resection.<sup>14</sup>

T2-weighted magnetic resonance imaging (MRI) is the key imaging study for diagnosis of MCL injuries. Intact, normal fibers of the MCL have low signal intensity, whereas MCL injury is reflected by an increased signal or a disruption of the continuity of the fibers. Thickened fibers on MRI may also indicate a prior injury. Localization of the injury may be ascertained on coronal views. Ambrose et al<sup>15</sup> showed that arthroscopic evaluation of the relationship between the medial femoral

condyle, medial meniscus, and medial tibial plateau is a useful diagnostic tool for localizing an MCL lesion.

Associated pathology, including meniscal tears and damage to the ACL, can also be detected on MRI and is helpful in guiding treatment. Miller et al<sup>16</sup> investigated the natural history of bone bruises, or trabecular microfractures, in patients with isolated MCL injuries. The authors noted a 45% incidence of bone bruising with MCL injuries; approximately half of these trabecular microfractures were associated with ACL tears. The lateral femoral condyle was most frequently involved, followed by the lateral tibial plateau. These lesions appear to be benign, and they resolve by 4 months without any osteochondral sequelae.

## Treatment

### Nonsurgical

The mainstay of treatment of isolated grade I and grade II MCL injuries continues to be nonsurgical, with an emphasis on early rehabilitation, including ROM with progression to strengthening exercises. Functional bracing with the use of a hinged knee brace allows early ROM while protecting the knee from a further valgus blow. Weight bearing is encouraged as soon as pain has subsided. Although rehabilitation protocols vary, the goals are identical: early ROM and weight bearing, followed by quadriceps and hamstring strengthening and conditioning with a gradual return to sports as pain subsides.

In one series, high school football players with grade I MCL injuries were able to return to play by an average of 10.6 days postinjury.<sup>17</sup> Those with grade II injuries treated nonsurgically were able to return by 19.5 days. Lundberg and Messner<sup>18</sup> prospectively observed 38 patients with

grade I or II MCL injuries that were treated nonsurgically. At 3 months after injury, 74% had returned to their preinjury activity level, and 95% had returned to work. The median Lysholm score was 96.5. Quadriceps muscle strength at 3 months was 97% versus that on the contralateral side. At 4 years, Lysholm scores improved to 100, with only mild decreases in Lysholm scores and activity noted at the 10-year observation. These results are compelling for continued nonsurgical treatment of grade I and II MCL injuries.

Creighton et al<sup>19</sup> reviewed the basic science of MCL healing with and without various treatments. They noted that the injured MCL undergoes four stages of healing: hemorrhage, inflammation, repair, and remodeling. The extra-articular environment of the MCL allows for abundant blood supply to be increased in times of stress, unlike the intra-articular environment of the ACL or PCL. Grade I and II injuries are characterized by primary repair of type I collagen, whereas grade III injuries, in which a gap is formed between the ends of the ligaments, are shown to have increased levels of type III collagen. Larger ligamentous gaps located at either end of the ligament heal more slowly than do smaller gaps and midsubstance tears. Multiple animal models have also shown that immobilization is a hindrance to ligament healing. Thornton et al<sup>20</sup> used a rabbit model to demonstrate that immobilization leads to significant differences in failure load at 6 and 14 weeks in the MCL-injured knee. These results reinforce the clinical importance of early mobilization in the MCL-injured knee.

Frank et al<sup>21</sup> evaluated injury location and its effect on MCL healing. Using a rabbit model, the authors demonstrated that histologically, ligament healing at femoral and tibial

interfaces exhibited abnormal callus formation and irregular resorption of local bone. Mechanically, injuries at the femur-ligament interface demonstrated the weakest viscoelastic and failure properties. MCL injuries at either bony interface healed more slowly than midsubstance injuries.

Although most isolated MCL injuries are successfully treated nonsurgically, the inherent properties of the MCL may remain compromised over the long-term. Recent studies have investigated the effects of modalities on MCL biomechanical characteristics and composition. Sparrow et al<sup>22</sup> explored the effects of ultrasound on healing of MCL injuries in rabbits. At 3 and 6 weeks postinjury, those specimens treated with ultrasound therapy had increased ratios of type I:type III collagen. Additionally, at 6 weeks, specimens in the ultrasound group had a 10% larger cross section with significant increases in ultimate load (40%) and energy absorption (69%). The effect of low-intensity ultrasound was revisited by Warden et al,<sup>23</sup> who also explored the effects of a nonsteroidal anti-inflammatory drug (ie, celecoxib) on MCL healing in a rat model. This study showed that ultrasound-treated specimens had improvements in strength (34.2%), stiffness (27.0%), and energy absorption (54.4%) at 2 weeks, suggesting that an early return to sport may be possible. Specimens treated with celecoxib absorbed significantly less energy (33.3%) at 2 weeks and had notable decreases in ultimate load to failure. This suggests that nonsteroidal anti-inflammatory drugs may have a modest but appreciable role in inhibiting early healing of knee ligaments. Trials of treating MCL injuries with gene therapy, growth factors, and small intestine submucosa are in their infancy but may hold promise with regard to restoring the biomechanical properties of the native ligament.

## Surgical

Surgical treatment of high-grade MCL injuries remains controversial. With regard to the treatment of isolated grade III tears, in the 1950s and 1960s, immediate surgical treatment was advocated. Ellsasser et al<sup>24</sup> showed good results with nonsurgical treatment in National Football League players in the 1970s. In the 1980s and 1990s, multiple series showed excellent results with both surgical and nonsurgical treatment.<sup>25-28</sup> Indelicato et al<sup>29</sup> reported excellent results with nonsurgical management of grade III MCL injuries in collegiate football players; the athletes returned to football at an average time of 9.2 weeks.

Our protocol for management of isolated grade III MCL injuries (opening at both 0° and 30°) involves a trial of nonsurgical treatment with emphasis on early functional rehabilitation. Surgical treatment is considered when the patient, particularly an elite athlete, notes persistent valgus laxity that compromises athletic function. Other findings that guide treatment include persistent laxity in the affected knee versus the contralateral knee on physical examination, as well as stress radiographs that are consistent with an incompetent MCL. Surgical treatment also may be warranted in the setting of an MCL avulsion injury with identification of a large bony fragment. Kuroda et al<sup>30</sup> demonstrated that a 4.5-mm cancellous screw could be used for reduction of an avulsed adductor tubercle corresponding to the origin of the MCL/POL, with suture reinforcement of the medial soft tissues.

Surgical fixation of the MCL has been routinely performed with primary repair, autografts, and allografts. Yoshiya et al<sup>31</sup> followed a cohort of 27 patients treated with semitendinosus and gracilis autografts and noted that 24 patients had normal or

nearly normal knee scores according to the International Knee Documentation Committee criteria. Additionally, under valgus stress testing, all patients had a side-to-side difference  $\leq 2$  mm. Reconstruction of the anterior fibers of the superficial MCL is of primary importance, but some authors advocate reconstruction of the POL in addition to the anterior MCL. Borden et al<sup>32</sup> described a double-bundle fixation technique using tibialis anterior allograft with 25 mm separating the tibial bone tunnels. By creating the second (ie, POL) limb, valgus stability is imparted even as the knee flexes beyond 45° when the anterior bundle is maximally taut.<sup>33</sup> The recommendation to reconstruct the POL is consistent with the results of Hughston and Eilers,<sup>34</sup> who showed its importance in rotation and valgus stability with knee flexion from 45° to 90°. Hughston<sup>35</sup> reported excellent long-term results with acute repair of both the MCL and POL even in patients with combined ACL/MCL injuries who did not undergo repair or reconstruction of the ACL.

## ACL/MCL Reconstruction

Reconstruction of multiple ligaments in a severely injured knee is based on specific patient demands, goals, and expectations. In the appropriate patient with combined ACL and MCL injury, surgical reconstruction of the ACL may be necessary to restore overall stability to the knee; discussion persists regarding the necessity of surgically addressing the MCL as well. In the early 1990s, Shelbourne and Porter<sup>36</sup> reported on 68 patients with combined ACL/MCL injury who underwent delayed surgical reconstruction of the ACL only, with nonsurgical management of the concomitant MCL injury. All patients underwent a rehabilitation protocol identical to those for patients with a

surgically treated isolated ACL injury. At an average of 2.3 years post-operatively, 95% of patients were able to resume their preinjury activity, with 66% of those returning to the same level of competition or above. Subjective outcomes, ROM, KT-1000 testing (MEDmetric, San Diego, CA), and strength scores were all favorable, indicating that nonsurgical management of the MCL injury did not compromise outcomes.

Noyes and Barber-Westin<sup>37</sup> reported the results of 46 patients with ACL/MCL injuries who were separated into two subsets. Patients in group 1 had ruptures of the ACL and all medial ligamentous structures (ie, MCL, POL, posteromedial capsule) as determined by opening to valgus stress at 0° and 30°. Patients in group 2 had ruptures of the ACL and the superficial MCL (ie, opening with valgus stress at 25°, but not at 0°). In group 1 (34 patients), both ligamentous injuries were surgically addressed, whereas in group 2 (12 patients), only the ACL was surgically reconstructed. At a mean 5.3-year follow-up, all patients in both groups had <3 mm of joint space opening at 0° and 25°, indicating that both surgical and nonsurgical treatment provided medial stability, and 96% of patients had resumed their preoperative ROM. However, patients in group 2 had better function of their ACL allografts as determined by arthrometer testing. Additionally, 55% of patients in group 1 returned to sports activities, whereas 75% of patients in group 2 did so. The authors noted that difference in treatment method and severity of injury could account for some of the variability in the results.

Millett et al<sup>38</sup> reported on 18 patients with combined ACL and grade II or grade III MCL injuries. All patients underwent early (<3 weeks) reconstruction of the ACL with nonsurgical treatment of the MCL

injury. At a minimum 2-year follow-up, good results were seen in functional outcomes, ROM, and strength. In addition, the mean Lysholm score was 94.5, and the mean Tegner activity score was 8.4. No difference in function or activity was seen in patients with grade II injury versus those with grade III MCL injury. These results were in contrast to earlier studies that advocated late reconstruction (>10 weeks) of the ACL. In a canine study, Woo et al<sup>39</sup> demonstrated that, compared with a knee with a transected ACL, an intact ACL provides a more stable environment and thus expedites MCL healing. Thus, early reconstruction would be favored to provide a nurturing environment for faster MCL healing.

We believe that the benefits of optimizing the environment for MCL healing from a biomechanical standpoint outweigh the risks of arthrofibrosis associated with ACL reconstruction. Zaffagnini et al<sup>40</sup> examined residual laxity in an in vivo model by comparing patients with isolated ACL injuries and those with combined ACL and grade II MCL injuries. With the aid of an intraoperative navigation system, the authors measured both anteroposterior and varus/valgus laxity before and after ACL reconstruction. Postoperatively, those with combined injuries had greater anteroposterior (average, 1.3 mm) and varus/valgus (average, 1°) laxity. The clinical implications, if any, of these differences were not reported.

Hillard-Sembell et al<sup>41</sup> examined late valgus instability in 66 patients with combined ACL/MCL injuries (11 ACL reconstruction/MCL repair, 33 ACL reconstruction only, 22 nonsurgical treatment) at a mean 35-month follow-up. Clinically, no valgus instability was seen in any patient. Radiographically, 13% of patients had a medial opening >2.5

mm versus the contralateral knee on stress views; this finding was independent of the method of treatment. The authors also measured anterior displacement, level of function, activity participation, and strength; they found no difference between patients treated with reconstruction of the ACL in an isolated ACL injury versus patients treated with reconstruction of the ACL alone for combined ACL/MCL injuries.

More recently, Halinen et al<sup>42</sup> conducted a prospective, randomized trial of 47 patients with combined knee injuries. All patients underwent early (<23 days) ACL reconstruction, and the MCL was surgically addressed in half of the patients. At a mean follow-up of 27 months, there were no differences between the groups with regard to knee function, stability, ROM, strength, and return to activity. In each group, the opening with valgus stress was not statistically significant compared with the contralateral side. Additionally, excellent or good Lysholm scores were found in 83% of patients in each group. The authors advocated early ACL reconstruction followed by 6 weeks of hinged knee bracing to protect the healing ligaments from large valgus forces.

Lundberg and Messner<sup>43</sup> explored the long-term effects of isolated MCL injuries in one group of patients and of combined ligamentous injuries of the knee in another group. At an average follow-up of 10 years, both groups had comparable knee function scores and activity levels. However, patients with combined injuries were noted to have increased sagittal laxity and radiographic signs of osteoarthritis. Additionally, the combined group was noted to have more reinjuries and subsequent surgeries.

In an attempt to identify those injuries that would necessitate MCL repair, Nakamura et al<sup>44</sup> correlated radio-

graphic with intraoperative findings. The authors used MRI to identify the location of the MCL lesion in 17 patients with combined ACL/grade III MCL injuries of the knee. After 6 weeks of bracing, all patients underwent surgical reconstruction of the ACL. Prior to ACL reconstruction, all patients underwent a stress radiograph under general anesthesia. Patients who had >4 mm of opening compared with the contralateral side underwent reconstruction of both the ACL and the superficial MCL with iliotibial tract graft. Increased valgus laxity was present preoperatively in all patients who had disruption of the MCL over the entire length of the superficial layer as seen on MRI, as opposed to isolated complete disruption at the femoral or tibial insertion sites. The authors noted a significant correlation between the location of the MCL insult on MRI and early residual valgus laxity, suggesting the usefulness of MRI in predicting outcomes of nonsurgical management of grade III MCL injuries.

Robins et al<sup>45</sup> examined the effect of location of MCL injury on postoperative ROM. All patients were treated with surgical reconstruction of the ACL and primary repair of the MCL. Postoperative recovery of ROM was significantly quicker (6 weeks) when the MCL injury was distal to the joint line rather than proximal to or at the level of the joint line. Additionally, the final ROM achieved was greater in those with injuries distal to the joint line, suggesting that the location of MCL injury plays a role in the rate and extent of return of ROM.

### ACL/PCL/MCL Combined Injuries

The available literature on ACL/PCL/MCL injuries is not nearly as extensive as that of isolated MCL in-

juries because the incidence of this combination of ligamentous insults is rare. The overwhelming consensus is that although ACL and PCL reconstruction is mandatory, the role of surgery in addressing the MCL is controversial. Some surgeons advocate early primary repair of the MCL, while others promote early PCL reconstruction and primary MCL repair with delayed reconstruction of the ACL.<sup>46-49</sup> Advocates of delayed ACL reconstruction report decreased rates of postoperative arthrofibrosis. With regard to stability, Fanelli et al<sup>50</sup> showed comparable results in eight knees treated with 4 to 6 weeks of bracing for MCL injury, followed by ACL/PCL reconstruction alone, compared with seven knees treated with primary MCL repair.

The authors' preferred method of treatment consists of functional rehabilitation for grade I and II MCL injuries. Grade III injuries are also treated nonsurgically with early functional rehabilitation in a knee brace. Persistent valgus laxity that interferes with daily activities or sports participation is treated surgically. For combined ACL/MCL injuries, the ACL is reconstructed after 6 weeks of brace wear and ROM exercises. Intraoperatively, the knee is placed under a valgus stress after the ACL has been reconstructed. If laxity persists on intraoperative physical examination (>4 mm versus the contralateral side at either 0° or 30°), then the MCL injury is treated surgically. This protocol is also followed for ACL/PCL/MCL injuries after reconstruction of the ACL and PCL.

### Summary

The MCL is the most frequently injured ligament in the knee, but such injury often goes unreported, particularly grade I and II injuries.<sup>1</sup> Knowledge of me-

dial knee anatomy and the mechanism of injury, along with a thorough physical examination and appropriate imaging, are of paramount importance in managing MCL injuries. Although research into prophylactic treatment and factors related to enhancing MCL healing is ongoing, a lack of consensus remains about surgical treatment of the MCL, particularly in combined ligamentous injuries. As the demand increases to return patients quickly to their preinjury activity level, whether recreational or professional, further studies are necessary to elucidate the optimal treatment of MCL injuries.

### References

*Evidence-based Medicine:* Level I/II studies include references 1, 2, 8, 11, 12, 16, 36, 39, and 41-44. Level III/IV studies (case reports and case-control cohort studies) include references 7, 14, 15, 17, 18, 23-25, 27, 28, 30, 34, 35, 37, and 40.

Citation numbers printed in **bold type** indicate references published within the past 5 years.

1. Miyasaka KC, Daniel DM, Stone ML: The incidence of knee ligament injuries in the general population. *Am J Knee Surg* 1991;4:3-8.
2. Sims WF, Jacobson KE: The posteromedial corner of the knee: Medial-sided injury patterns revisited. *Am J Sports Med* 2004;32:337-345.
3. Warren LF, Marshall JL: The supporting structures and layers on the medial side of the knee: An anatomical analysis. *J Bone Joint Surg Am* 1979;61:56-62.
4. Robinson JR, Sanchez-Ballester J, Bull AM, Thomas Rde W, Amis AA: The posteromedial corner revisited: An anatomical description of the passive restraining structures of the medial aspect of the human knee. *J Bone Joint Surg Br* 2004;86:674-681.
5. Wymenga AB, Kats JJ, Kooloos J, Hillen B: Surgical anatomy of the medial collateral ligament and the posteromedial capsule of the knee. *Knee Surg Sports Traumatol Arthrosc* 2006;



- 14:229-234.
6. Gardiner JC, Weiss JA, Rosenberg TD: Strain in the human medial collateral ligament during valgus loading of the knee. *Clin Orthop Relat Res* 2001;391:266-274.
  7. Fetto JF, Marshall JL: Medial collateral ligament injuries of the knee: A rationale for treatment. *Clin Orthop Relat Res* 1978;132:206-218.
  8. Albright JP, Powell JW, Smith W, et al: Medial collateral ligament knee sprains in college football: Brace wear preferences and injury risk. *Am J Sports Med* 1994;22:2-11.
  9. Brown TD, Van Hoeck JE, Brand RA: Laboratory evaluation of prophylactic knee brace performance under dynamic valgus loading using a surrogate leg model. *Clin Sports Med* 1990;9:751-762.
  10. Najibi S, Albright JP: The use of knee braces: Part 1. Prophylactic knee braces in contact sports. *Am J Sports Med* 2005;33:602-611.
  11. Greene DL, Hamson KR, Bay RC, Bryce CD: Effects of protective knee bracing on speed and agility. *Am J Sports Med* 2000;28:453-459.
  12. Sitler M, Ryan J, Hopkinson W, et al: The efficacy of a prophylactic knee brace to reduce knee injuries in football: A prospective, randomized study at West Point. *Am J Sports Med* 1990;18:310-315.
  13. American Medical Association: Committee on the Medical Aspects of Sports: *Standard Nomenclature of Athletic Injuries*. Chicago, IL: American Medical Association, 1966.
  14. Muschol M, Müller I, Petersen W, Hassenpflug J: Symptomatic calcification of the medial collateral ligament of the knee joint: A report about five cases. *Knee Surg Sports Traumatol Arthrosc* 2005;13:598-602.
  15. Ambrose HC, Simonian PT, Sims WF: Arthroscopic localization of medial collateral ligament injury: Report of 2 cases in adults. *Arthroscopy* 2001;17:E21.
  16. Miller MD, Osborne JR, Gordon WT, Hinkin DT, Brinker MR: The natural history of bone bruises: A prospective study of magnetic resonance imaging-detected trabecular microfractures in patients with isolated medial collateral ligament injuries. *Am J Sports Med* 1998;26:15-19.
  17. Derscheid GL, Garrick JG: Medial collateral ligament injuries in football: Nonoperative management of grade I and grade II sprains. *Am J Sports Med* 1981;9:365-368.
  18. Lundberg M, Messner K: Long-term prognosis of isolated partial medial collateral ligament ruptures: A ten-year clinical and radiographic evaluation of a prospectively observed group of patients. *Am J Sports Med* 1996;24:160-163.
  19. Creighton RA, Spang JT, Dahners LE: Basic science of ligament healing: Medial collateral ligament healing with and without treatment. *Sports Med Arthrosc Rev* 2005;13:145-150.
  20. Thornton GM, Johnson JC, Maser RV, Marchuk LL, Shrive NG, Frank CB: Strength of medial structures of the knee joint are decreased by isolated injury to the medial collateral ligament and subsequent joint immobilization. *J Orthop Res* 2005;23:1191-1198.
  21. Frank CB, Loitz BJ, Shrive NG: Injury location affects ligament healing: A morphologic and mechanical study of the healing rabbit medial collateral ligament. *Acta Orthop Scand* 1995;66:455-462.
  22. Sparrow KJ, Finucane SD, Owen JR, Wayne JS: The effects of low-intensity ultrasound on medial collateral ligament healing in the rabbit model. *Am J Sports Med* 2005;33:1048-1056.
  23. Warden SJ, Avin KG, Beck EM, DeWolf ME, Hagemeyer MA, Martin KM: Low-intensity pulsed ultrasound accelerates and a nonsteroidal anti-inflammatory drug delays knee ligament healing. *Am J Sports Med* 2006;34:1094-1102.
  24. Ellsasser JC, Reynolds FC, Omohundro JR: The non-operative treatment of collateral ligament injuries of the knee in professional football players: An analysis of seventy-four injuries treated non-operatively and twenty-four injuries treated surgically. *J Bone Joint Surg Am* 1974;56:1185-1190.
  25. Hughston JC, Barrett GR: Acute anteromedial rotatory instability: Long-term results of surgical repair. *J Bone Joint Surg Am* 1983;65:145-153.
  26. Jones RE, Henley MB, Francis P: Nonoperative management of isolated grade III collateral ligament injury in high school football players. *Clin Orthop Relat Res* 1986;213:137-140.
  27. Muller W: *The Knee: Form, Function, and Ligament Reconstruction*. New York, NY: Springer-Verlag, 1983.
  28. Reider B, Sathy MR, Talkington J, Blyznak N, Kollias S: Treatment of isolated medial collateral ligament injuries in athletes with early functional rehabilitation: A five-year follow-up study. *Am J Sports Med* 1994;22:470-477.
  29. Indelicato PA, Hermansdorfer J, Huegel M: Nonoperative management of complete tears of the medial collateral ligament of the knee in intercollegiate football players. *Clin Orthop Relat Res* 1990;256:174-177.
  30. Kuroda R, Muratsu H, Harada T, et al: Avulsion fracture of the posterior oblique ligament associated with acute tear of the medial collateral ligament. *Arthroscopy* 2003;19:E18.
  31. Yoshiya S, Kuroda R, Mizuno K, Yamamoto T, Kurosaka M: Medial collateral ligament reconstruction using autogenous hamstring tendons: Technique and results in initial cases. *Am J Sports Med* 2005;33:1380-1385.
  32. Borden PS, Kantaras AT, Caborn DN: Medial collateral ligament reconstruction with allograft using a double-bundle technique. *Arthroscopy* 2002;18:E19.
  33. Warren LA, Marshall JL, Girgis F: The prime static stabilizer of the medial side of the knee. *J Bone Joint Surg Am* 1974;56:665-674.
  34. Hughston JC, Eilers AF: The role of the posterior oblique ligament in repairs of acute medial (collateral) ligament tears of the knee. *J Bone Joint Surg Am* 1973;55:923-940.
  35. Hughston JC: The importance of the posterior oblique ligament in repairs of acute tears of the medial ligaments in knees with and without an associated rupture of the anterior cruciate ligament: Results of long-term follow-up. *J Bone Joint Surg Am* 1994;76:1328-1344.
  36. Shelbourne KD, Porter DA: Anterior cruciate ligament-medial collateral ligament injury: Nonoperative management of medial collateral ligament tears with anterior cruciate ligament reconstruction: A preliminary report. *Am J Sports Med* 1992;20:283-286.
  37. Noyes FR, Barber-Westin SD: The treatment of acute combined ruptures of the anterior cruciate and medial ligaments of the knee. *Am J Sports Med* 1995;23:380-389.
  38. Millett PJ, Pennock AT, Sterett WI, Steadman JR: Early ACL reconstruction in combined ACL-MCL injuries. *J Knee Surg* 2004;17:94-98.
  39. Woo SL, Young EP, Ohland KJ, Marcin JP, Horibe S, Lin HC: The effects of transection of the anterior cruciate ligament on healing of the medial collateral ligament: A biomechanical study of the knee in dogs. *J Bone Joint Surg Am* 1990;72:382-392.
  40. Zaffagnini S, Bignozzi S, Martelli S, Lopomo N, Marcacci M: Does ACL reconstruction restore knee stability in combined lesions? An in vivo study. *Clin Orthop Relat Res* 2007;454:95-99.
  41. Hillard-Sembell D, Daniel DM, Stone ML, Dobson BE, Fithian DC: Combined injuries of the anterior cruciate and

- medial collateral ligaments of the knee: Effect of treatment on stability and function of the joint. *J Bone Joint Surg Am* 1996;78:169-176.
42. Halinen J, Lindahl J, Hirvensalo E, Santavirta S: Operative and nonoperative treatments of medial collateral ligament rupture with early anterior cruciate ligament reconstruction: A prospective randomized study. *Am J Sports Med* 2006;34:1134-1140.
43. Lundberg M, Messner K: Ten-year prognosis of isolated and combined medial collateral ligament ruptures: A matched comparison in 40 patients using clinical and radiographic evaluations. *Am J Sports Med* 1997;25:2-6.
44. Nakamura N, Horibe S, Toritsuka Y, Mitsuoka T, Yoshikawa H, Shino K: Acute grade III medial collateral ligament injury of the knee associated with anterior cruciate ligament tear: The usefulness of magnetic resonance imaging in determining a treatment regimen. *Am J Sports Med* 2003;31:261-267.
45. Robins AJ, Newman AP, Burks RT: Postoperative return of motion in anterior cruciate ligament and medial collateral ligament injuries: The effect of medial collateral ligament rupture location. *Am J Sports Med* 1993;21:20-25.
46. Azar FM, Aaron DG Jr : Surgical treatment of anterior cruciate ligament-posterior cruciate ligament-medial side knee injuries. *J Knee Surg* 2005;18:220-227.
47. Fanelli GC, Edson CJ, Orcutt DR, Harris JD, Zijerdi D: Treatment of combined anterior cruciate-posterior cruciate ligament-medial-lateral side knee injuries. *J Knee Surg* 2005;18:240-248.
48. Klimkiewicz JJ, Petrie RS, Harner CD: Surgical treatment of combined injury to anterior cruciate ligament, posterior cruciate ligament, and medial structures. *Clin Sports Med* 2000;19:479-492.
49. Phisitkul P, James SL, Wolf BR, Amendola A: MCL injuries of the knee: Current concepts review. *Iowa Orthop J* 2006;26:77-90.
50. Fanelli GC, Giannotti BF, Edson CJ: Arthroscopically assisted combined anterior and posterior cruciate ligament reconstruction. *Arthroscopy* 1996;12:5-14.